



Séminaire  
**Winter Arrhythmia**  
School  
*Annual Cardiac Arrhythmia Meeting*  
*Division of Cardiology, University of Toronto*

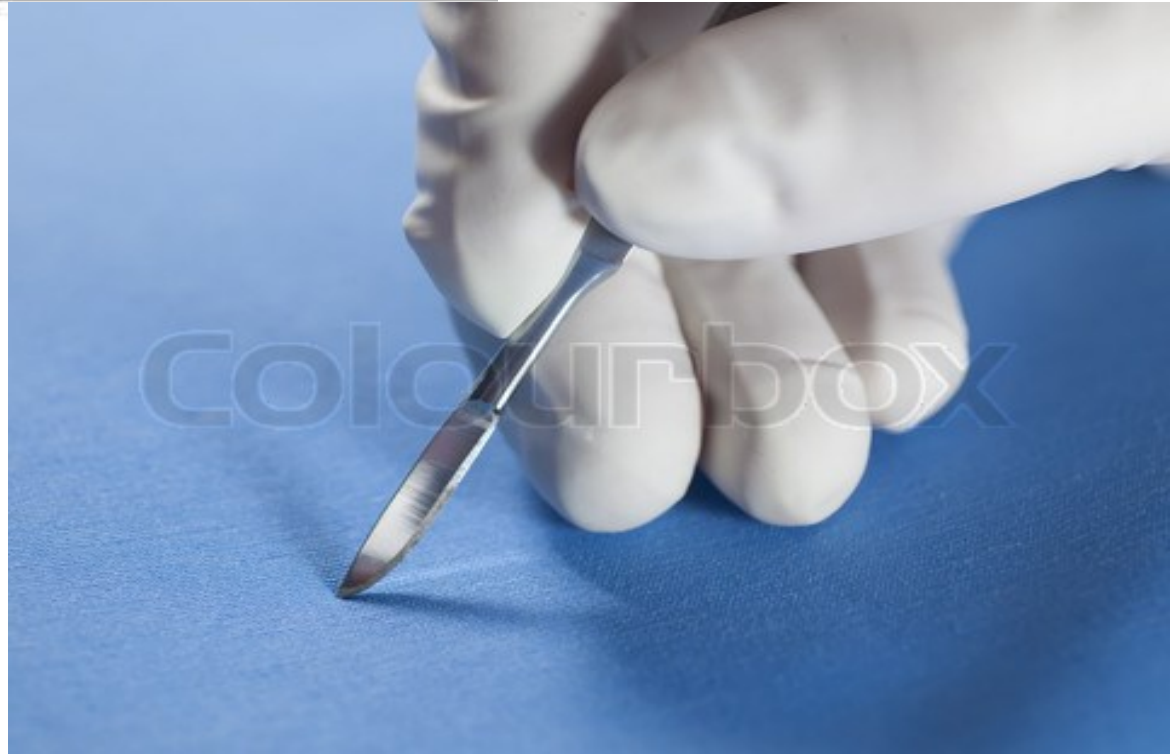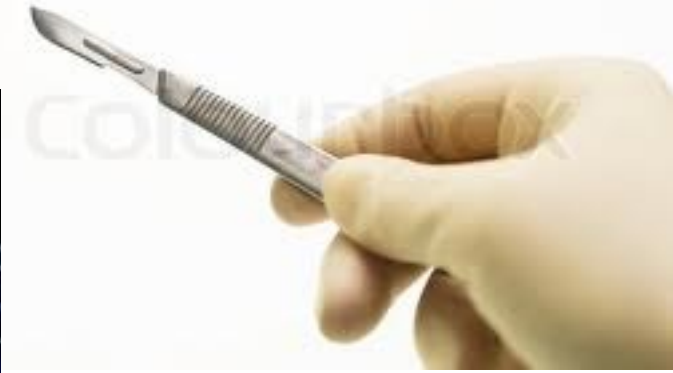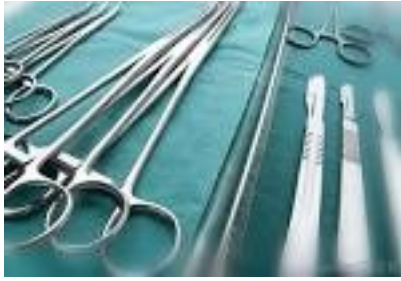# Surgical Approach to CRT

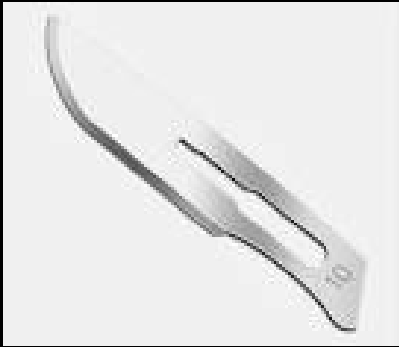Fuad Moussa, MD, FRCSC

Sunnybrook Health Sciences Centre

**14<sup>th</sup> Annual**

**Collingwood, Ontario,  
February 10 -12, 2017**







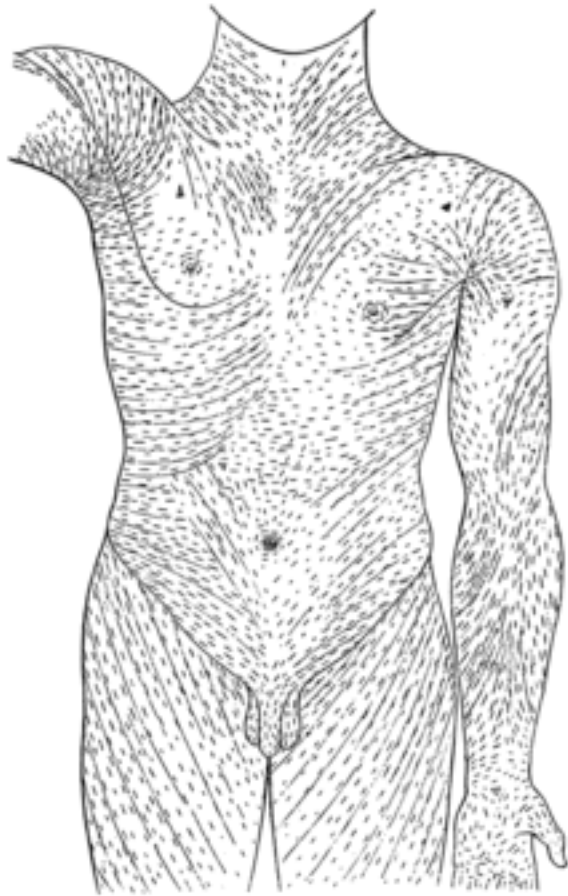
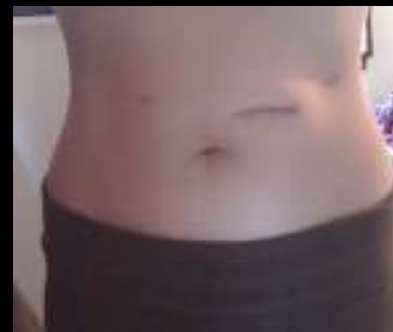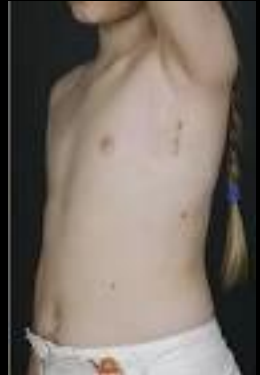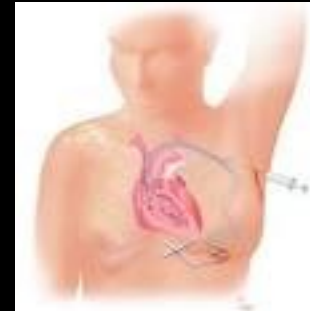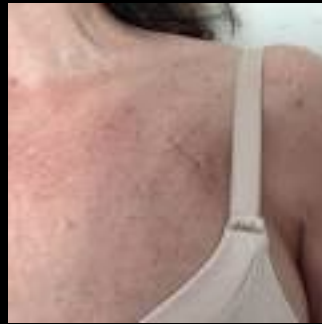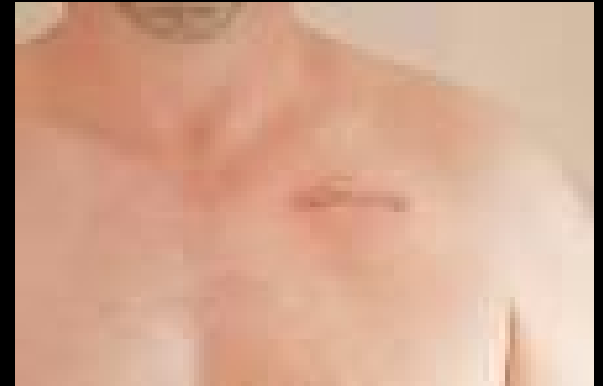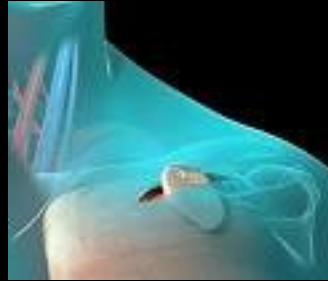
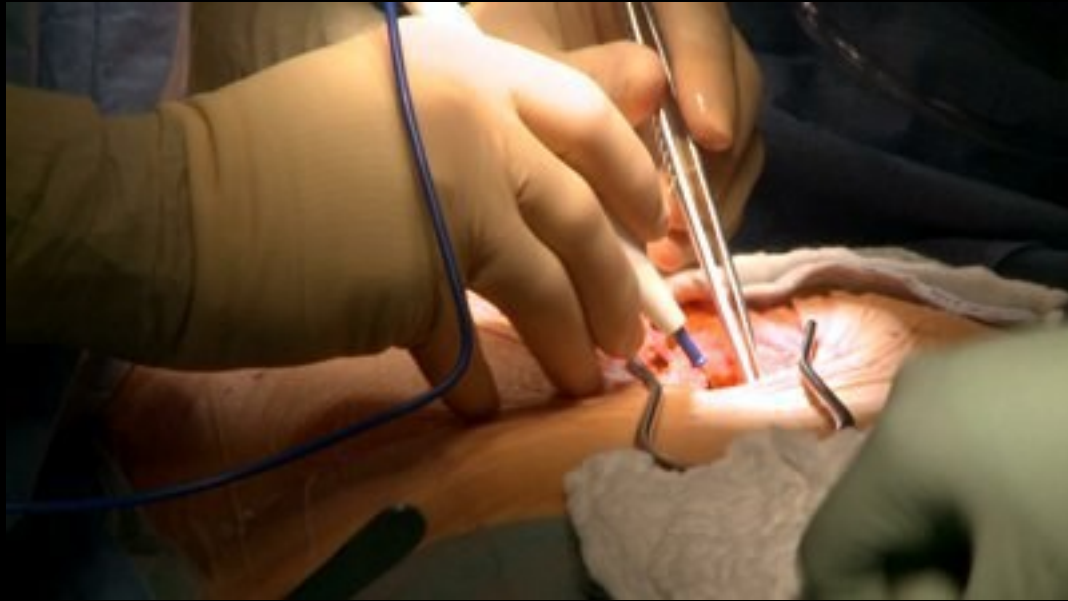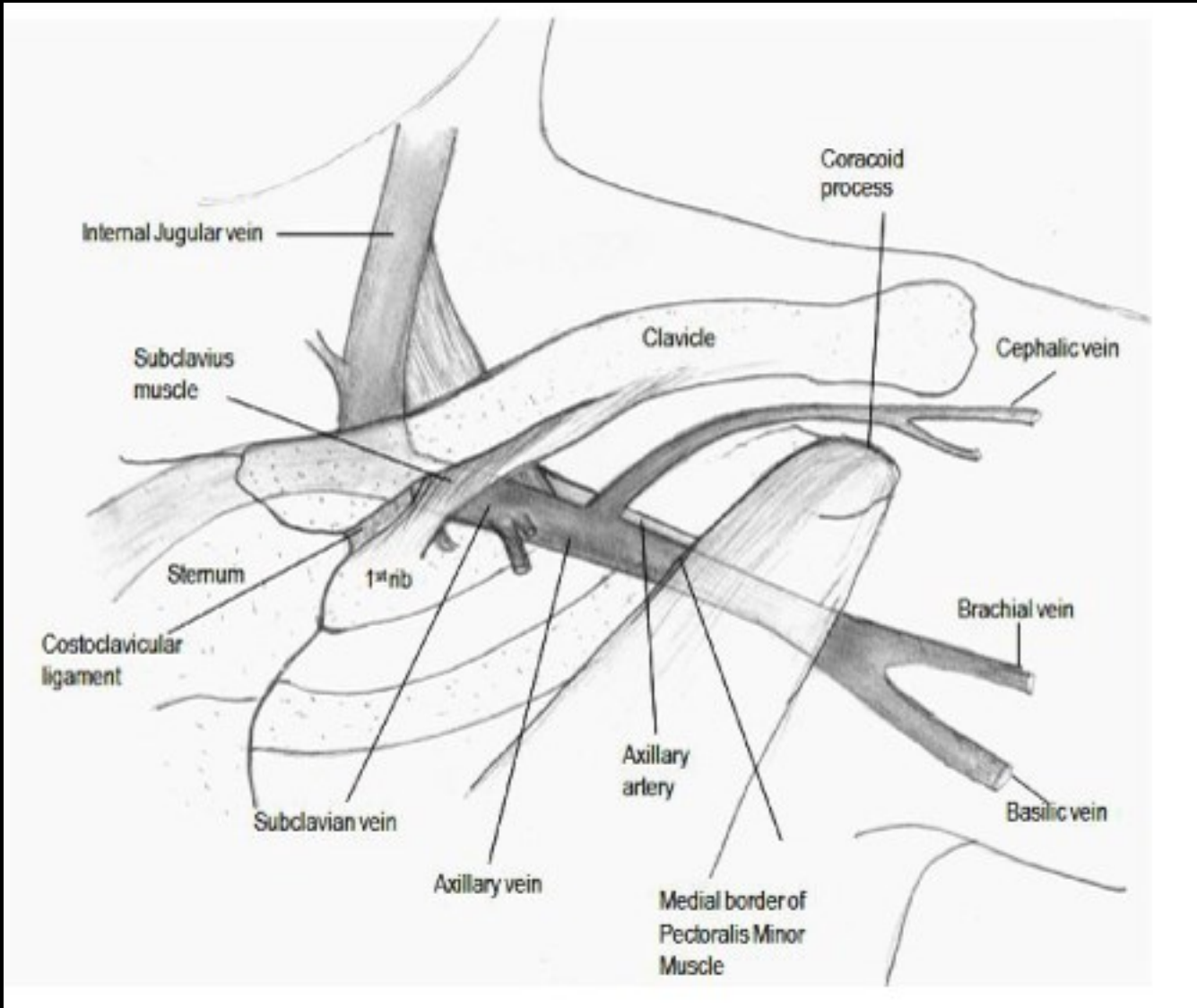


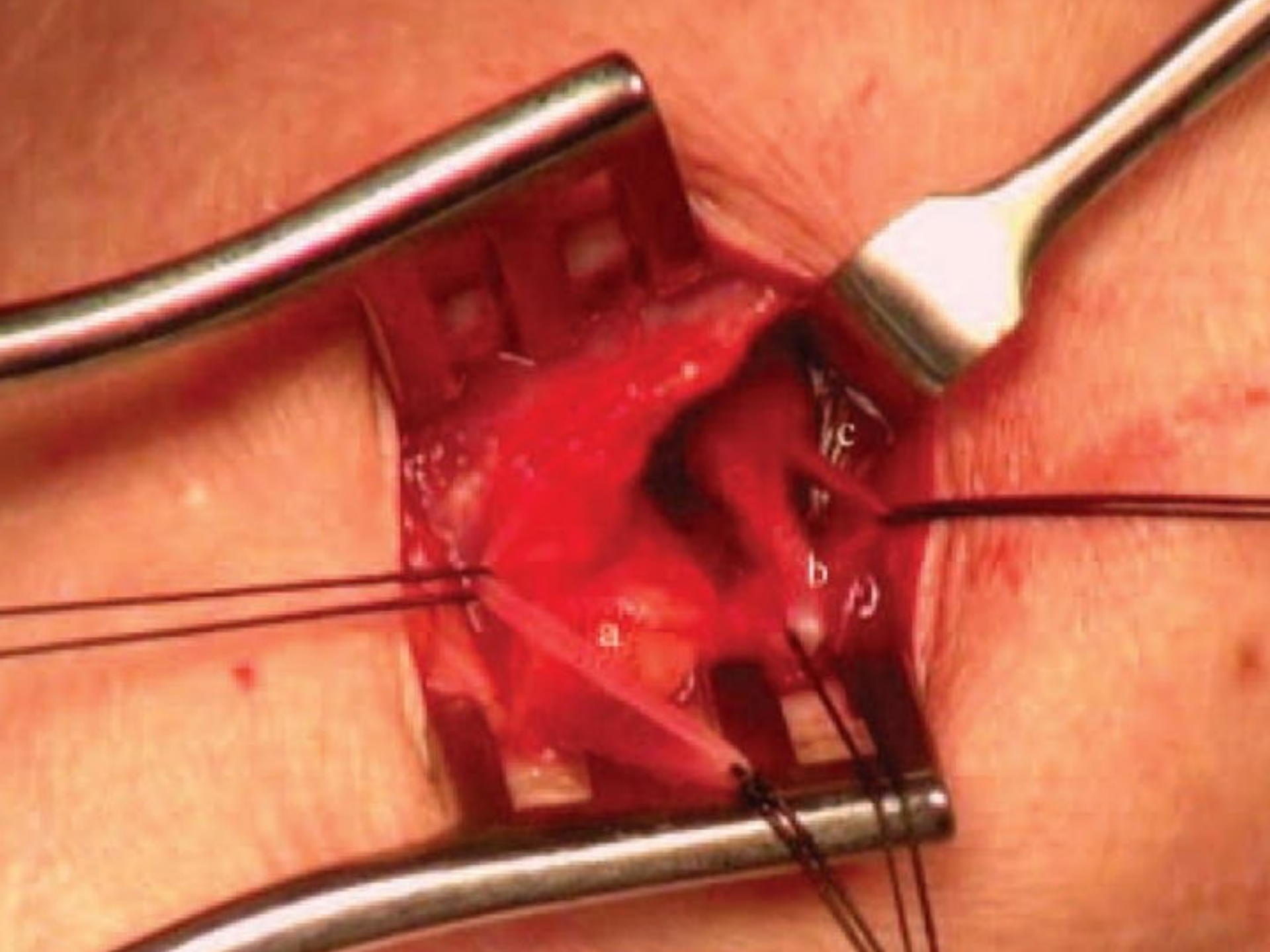
Fig. 838.

Die Spaltrichtungen der Haut. (C. Langer.)



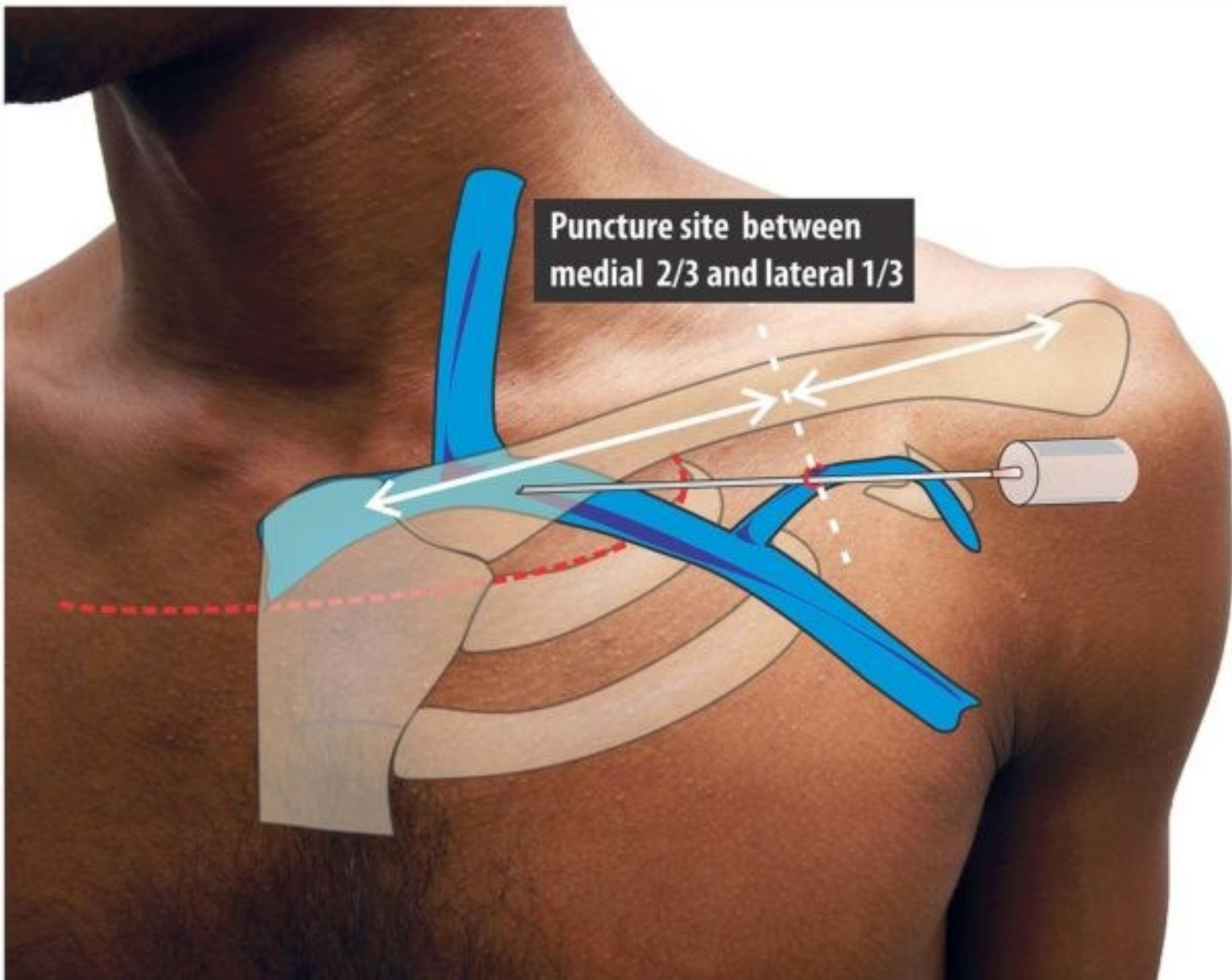


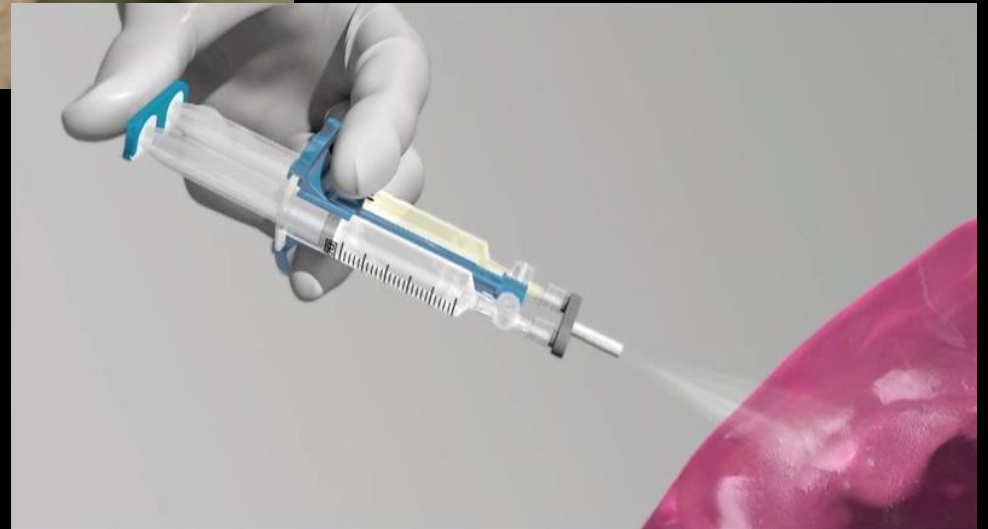
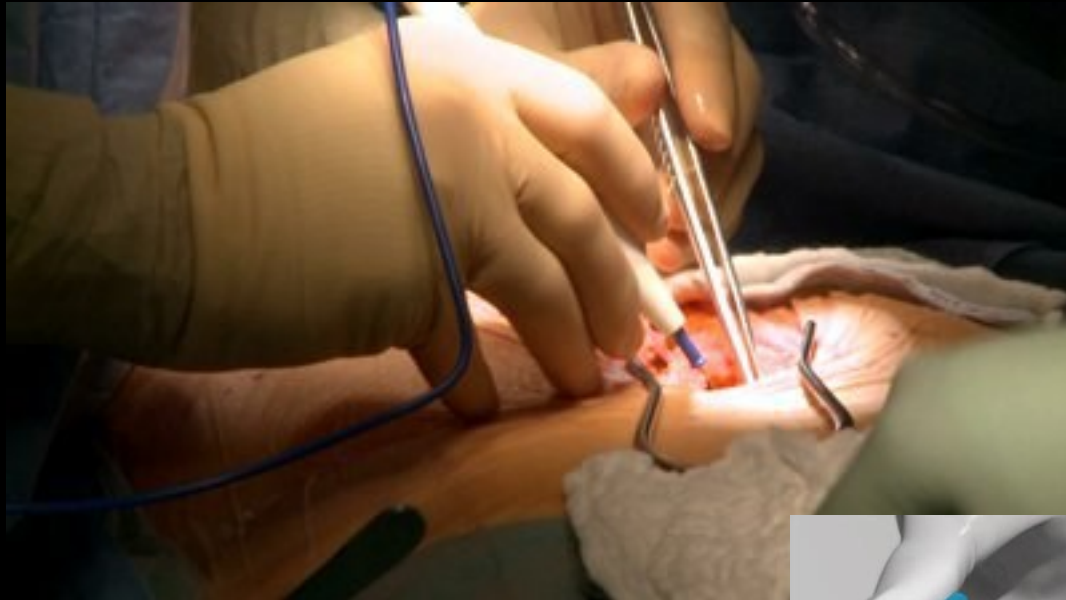
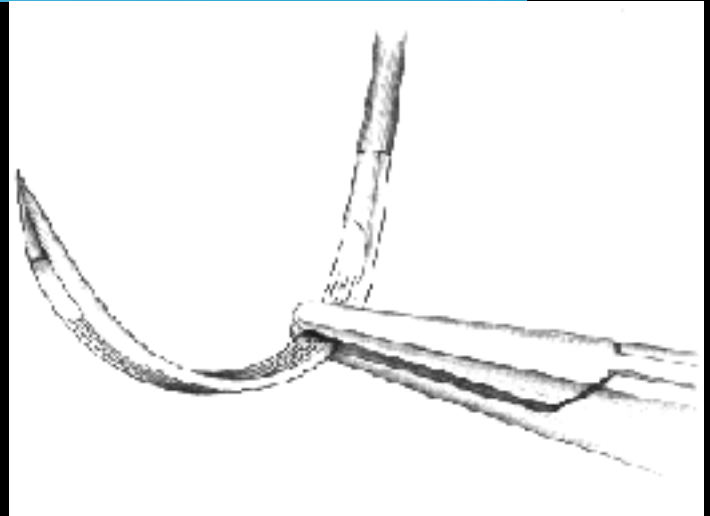
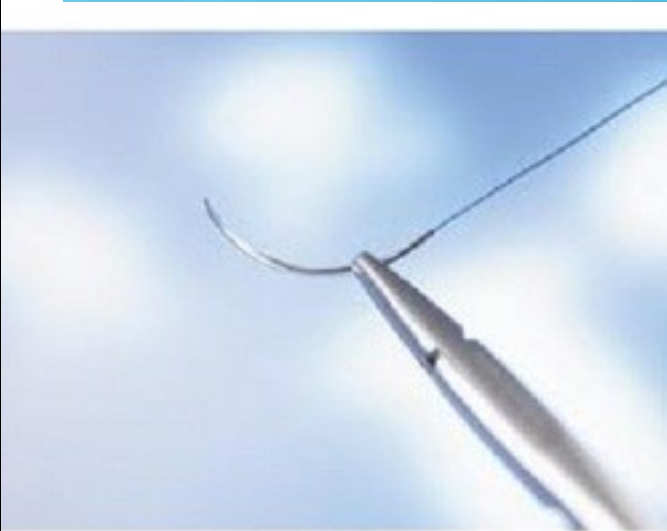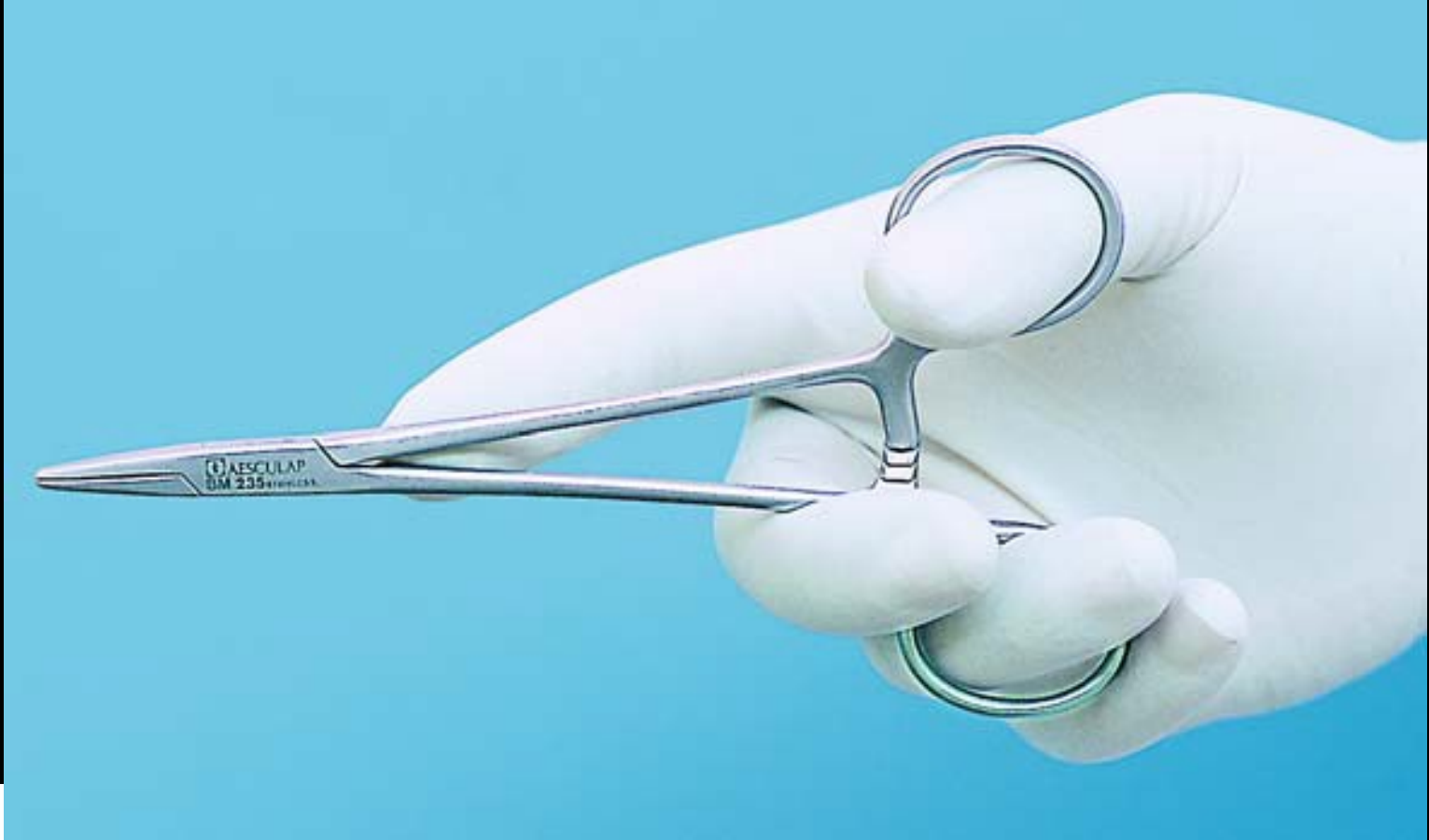





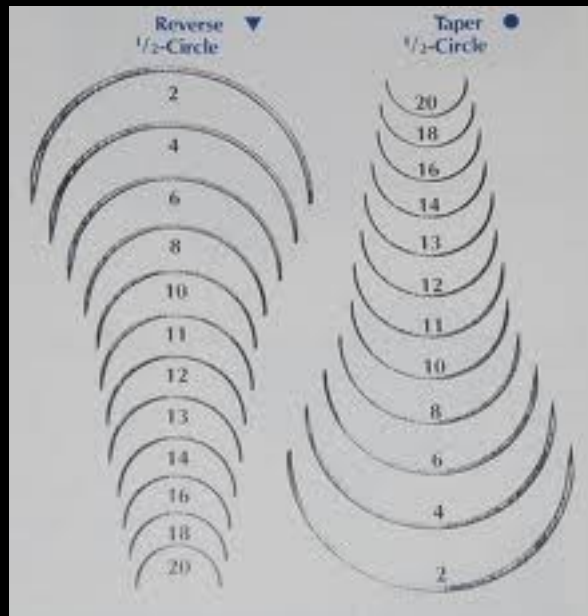
Puncture site between medial 2/3 and lateral 1/3

















DESCRIPTION OF NEEDLE TYPE

針尖型式	POINT TYPE	SYMBOL
	TAPER POINT	●
	BLUNT TAPER POINT	○
	CUTTING EDGE	▲
	REVERSE CUTTING EDGE	▼
	TAPERCUT	⊙
	MICRO-POINT SPATULA CURVED	◄

